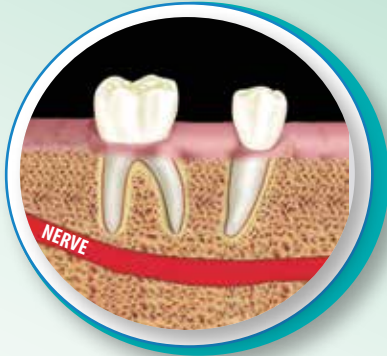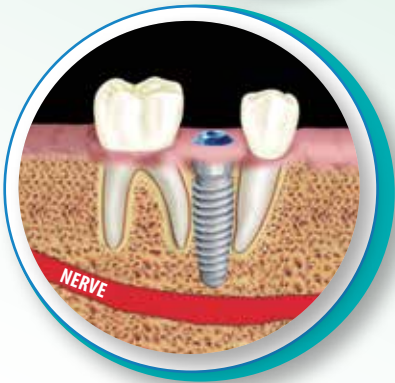


# MANDIBLE HEIGHT

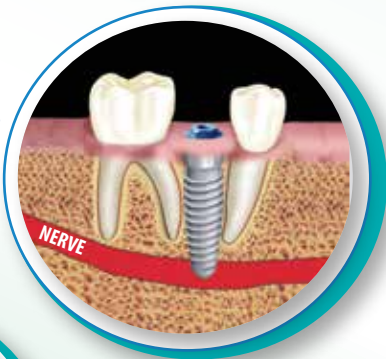
Position of nerve in the lower jaw bone is critical to success without complications.



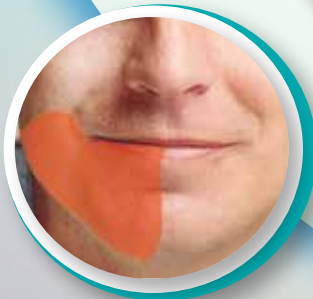In this example there is **Adequate** bone height to place the implant safely.



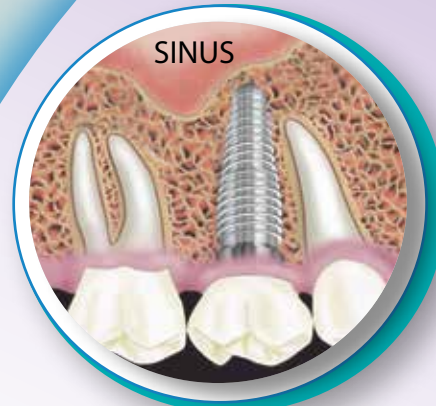In this example there is **Inadequate** bone height to place the implant without damage to the nerve.



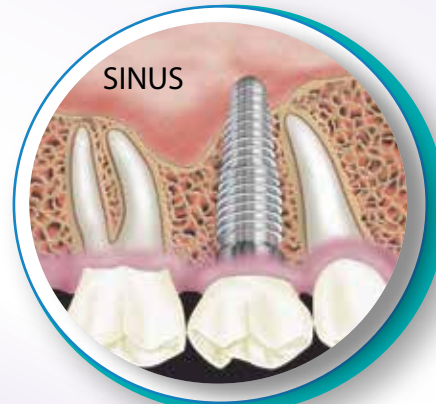If the nerve is damaged, the red area indicates where you would be "numb".



# MAXILLA HEIGHT



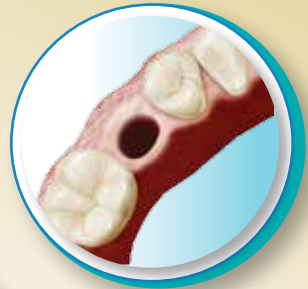In this patient the maxillary sinus (a natural air space) is high, and placement of a dental implant is possible without further grafting.



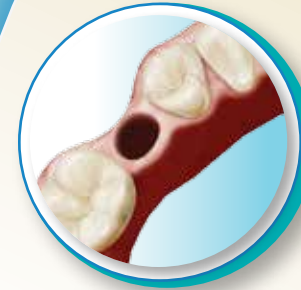
In this patient the maxillary sinus is too low. The implant will be sticking up into the air of the sinus. Further grafting will be necessary before an implant can be placed for this patient.

# RIDGE WIDTH

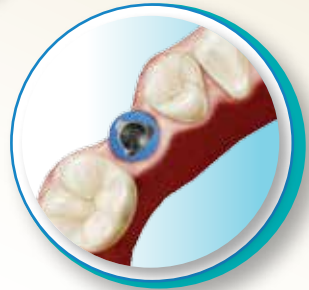The extraction leaves a hole in the bone.



If not grafted, the bone shrinks in width.



In this example, the width of the bone does not allow placement of a dental implant.



However, with a bone graft, the width of the bone after healing is maintained and dental implant placement is possible.

